

CASE SERIES AND REPORTS

Temporo-mandibular joint chondrosarcoma: Case report and review of the literature

Condrosarcoma dell'articolazione temporo-mandibolare: caso clinico e revisione della letteratura

C. GIORGIONE, F.M. PASSALI, T. VARAKLIOTIS, M. SIBILIA, F. OTTAVIANI
Department of Otorhinolaryngology, Tor Vergata University Hospital, Rome, Italy

SUMMARY

Chondrosarcoma is a malignant mesenchymal tumour of cartilaginous origin. It represents 11% of all malignant primary bone tumours, and the pelvis, ribs, femur and humerus are most frequently involved. Chondrosarcoma of the head and neck region is a rare disease, and represents approximately 0.1% of all head and neck neoplasms. This report describes a rare localisation of chondrosarcoma in a 56-year-old man who presented with swelling in the right preauricular area and mild limitation and pain in the mouth opening. Since 1959, just a few cases of temporomandibular joint (TMJ) chondrosarcoma have been described. Computed tomography revealed a large mass (39 x 46 x 40 mm) in the right preauricular and parotid region with morpho-structural alterations of the condyle and an intense periostotic reaction. The tumour was treated by total parotidectomy and condylotomy. The VII cranial nerve was preserved. Histopathologic examination revealed a low grade chondrosarcoma with a 50% proliferation index. At present, the patient is still receiving routine follow-up after radiotherapy and physiotherapy.

KEY WORDS: Chondrosarcoma • Temporomandibular joint • Bone tumour

RIASSUNTO

Il condrosarcoma è un tumore mesenchimale maligno di derivazione cartilaginea. Rappresenta l'11% dei tumori maligni ossei primari e si localizza prevalentemente a livello della pelvi, del femore distale e dell'omero prossimale. Il condrosarcoma della regione testa-collo rappresenta circa lo 0,1% delle neoplasie di questo distretto e l'origine nell'articolazione temporo-mandibolare è un evento raro. Solo 23 casi fino ad oggi sono stati descritti in letteratura dal 1954 ad oggi. Questo report tratta di un caso di condrosarcoma avente come origine il condilo mandibolare in un paziente maschio di 56 anni giunto alla nostra osservazione per la presenza di una neoformazione di consistenza duro-ligneo localizzata nella regione parotideo destra, otalgia, dolore alla masticazione e trisma. La TC evidenziava voluminosa neoformazione (39x46x40mm) che inglobava posteriormente la branca montante della mandibola, con alterazioni morfostrutturali del condilo ed intensa reazione periostotica. Il condilo mandibolare appariva inoltre lussato anteriormente. È stato eseguito intervento chirurgico di parotidectomia totale con conservazione del facciale e mandibolectomia parziale. L'esame istologico associato all'immunoistochimica ha evidenziato un condrosarcoma ben differenziato, con indice proliferativo pari al 50%. Ad oggi il paziente esegue routinariamente follow-up con controlli ambulatoriali dopo aver effettuato trattamento radio e fisioterapico.

PAROLE CHIAVE: *Condrosarcoma • Articolazione temporomandibolare • Tumori ossei*

Acta Otorhinolaryngol Ital 2015;35:208-211

Introduction

Chondrosarcoma is a slow-growing malignant tumour characterised by the formation of cartilage, but not bone, by tumour cells. Chondrosarcoma arises from embryogenic cartilaginous rests¹. It seldom occurs in the head and neck region, especially the mandible, and can be found even more rarely in the temporo-mandibular joint (TMJ).

Clinical presentation usually mimics more common disorders, leading to delay in diagnosis (unilateral facial swell-

ing, external auditory canal obstruction or chronic TMJ dysfunction)¹. The clinical behaviour of chondrosarcoma is greatly variable and is linked to histologic grading. The aetiology of chondrosarcomas still remains unclear and their management is controversial. The following report describes a rare case of TMJ chondrosarcoma.

Case report

A 56-year-old east European male was referred to our hospital with right auricular pain that had been present for 12

months and treated with antibiotic and anti-inflammatory therapy without any benefits. The patient also reported a progressive painless mass growth in his right pre-auricular region for 3 months, with mild limitation in the mouth opening and pain on chewing. He denied any trauma.

Objective clinical exam showed facial asymmetry and swelling in the right pre-auricular region.

Ultrasound of the preauricular region, performed in the emergency department, showed a roundish mass 45 x 34 x 29 mm, with parenchymatous echotexture, heterogeneous with calcifications in the context, in close proximity to the parotid gland. In addition, perilesional and intralesional vascularisation was observed.

During hospitalisation, the patient was in good general conditions, with a hard mass in his right parotid region fixed to the deep cervical structure and covered with mild hyperaemic skin. He had trisma and right auricular pain. There were no palpable cervical lymph nodes and no VII cranial facial nerve palsy.

A fine-needle aspiration biopsy of the mass was reported as a pleomorphic adenoma, but due to some myoepithelial cellular characteristics, the pathologist suggested postponing definitive diagnosis until the entire mass could be examined. A head and neck CT scan was performed which revealed a large mass with a hyperintense wall and colligation inside. Its size was 39 x 46 x 40 mm (Fig. 1).

This mass arose from the posterior mandibular branch and presented a partial structural erosion of the condyle with high periostotic reaction. This mass showed a swelling in the region of the masseter muscle and close to the bone portion of the external acoustic meatus.

After CT, a MRI was performed (Fig. 2).

The functionality of the facial nerve, evaluated by electromyography of the orbicularis oculi and oris muscles, was normal.

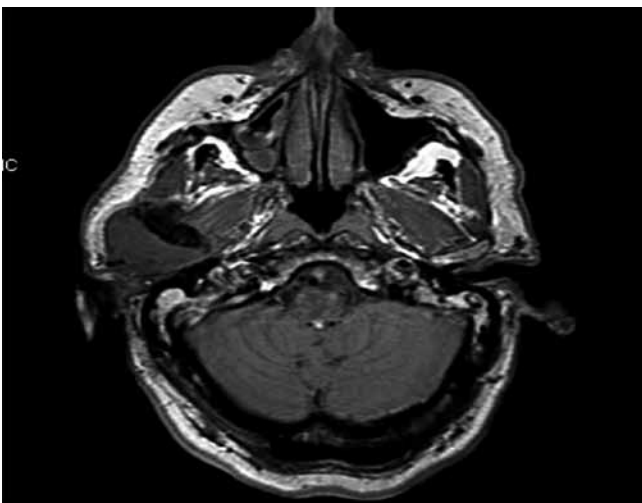


Fig. 1. CT image showing a voluminous mass with hyperdense wall, determining structural alteration of the condyle and an intense periostotic reaction. Furthermore, the lesion appears to be in contact with the front wall of the external acoustic meatus.

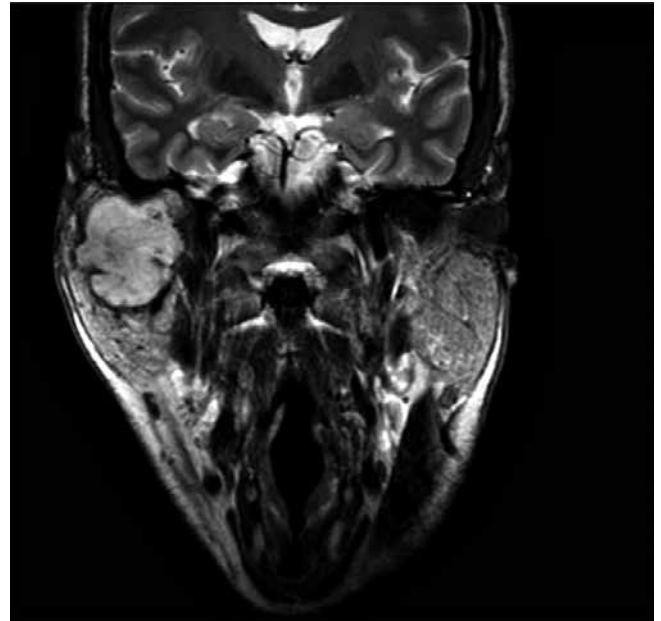


Fig. 2. MRI image showing an expansive mass with liquid content inside an irregular and thickened wall. It also shows inhomogeneous and widespread contrast enhancement.

A total parotidectomy and condylectomy was carried out. The VII cranial nerve was preserved, and during surgery functionality was checked by intraoperative nerve monitoring (NIM). The final histologic diagnosis of the mass was "low grade chondrosarcoma". Microscopic examination of the section showed chondroid tissue, large cells with atypical nuclei and a proliferative index of 50% (Ki-67) (Fig. 3). Immunohistochemically, cells were S100+, CK35BH11-, actin-, vimentin+ ck19-, GFAP- and PANCK-.

After surgery the patient had grade II-III facial nerve paralysis which regressed to a grade II when the patient was discharged (10 days after surgery) (Fig. 4).

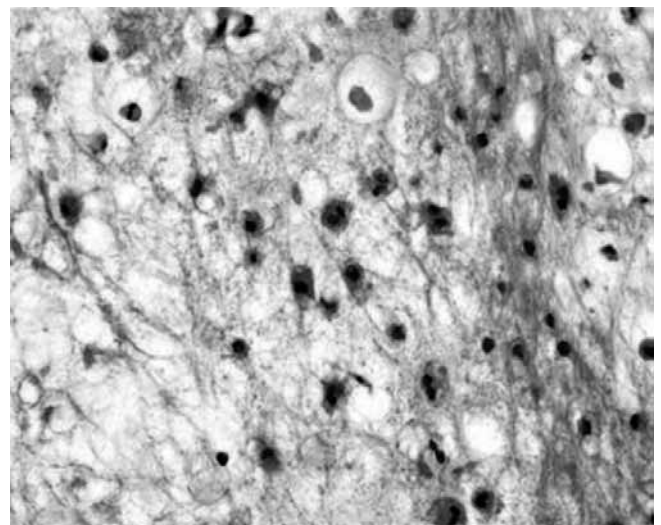


Fig. 3. Histologic image of TMJ chondrosarcoma showing atypical chondrocytes with binucleation and eosinophilic cytoplasm.

He was referred for radiation therapy after an oncologic and radiotherapeutic evaluation because of dubious positive margins of the surgical specimen.

At present, he is undergoing radiotherapy and has completed physiotherapy for the VII cranial nerve. The patient is still receiving routine follow-up at the time of writing (Fig. 5).

Discussion

After osteogenic sarcoma, chondrosarcoma is the most common bone tumour and represents 10-20% of all primary bone tumours². The primary sites of presentation are the pelvis, femur and humerus^{3,1}. Chondrosarcoma of the head and neck region is a rare disease, and only 5-10% of chondrosarcoma occur in the head and neck. Larynx, maxilla and nasal region are the most common sites². The occurrence of chondrosarcoma in TMJ is an exceptional event that has been described in only 23 cases.

Chondrosarcoma can be primary or secondary depending on whether it develops *ex novo* (from normal cartilage, bones or soft tissue) or from a pre-existent benign lesion in patients with Maffucci syndrome, Ollier disease, etc.

No history of bone-cartilage disease or familial skeleton disease was found in the present patient.

Evans classified conventional chondrosarcoma into three grades (I-II, III) based on cellularity, frequency of mitosis and nuclear dimension. It is also possible to divide chondrosarcoma into two groups: low grade (Evans' grade I-II) and high grade (Evans' grade III)⁴.

Low grade chondrosarcoma (grade I) is very close in appearance to enchondromas and osteochondromas, has occasional binucleated cells and may show atypical cells including binucleate forms (cells with two nuclei instead of one). Calcifications and bone formation can be found, but can also be characteristic of higher grade tumours.

Grade II (or "intermediate grade") presents a higher cellular population with a greater degree of nuclear atypia, hyperchromasia and nuclear size. The mitotic rate is low (less than two per 10 high power fields). High grade (grade III) chondrosarcoma has significant areas of marked pleomorphism, large cells with more hyperchromatic, denser and greater nuclei size than grade II, occasional giant cells and abundant necrosis. Mitoses are more than three per field⁴.

Histologic differentiation influences clinical behaviour, and the metastasis rate varies from 10% for grade II cases to 71% for those in grade III. The most frequent metastatic sites are the limbs and lungs. The 5-year survival rate varies from 90% to 81% to 43%, respectively, for grades I, II and III. Metastasis from grade I chondrosarcoma has not been reported⁵.

Chondrosarcoma has several histologic types, although the conventional type is the most common. Other types include clear cell, myxoid, mesenchymal

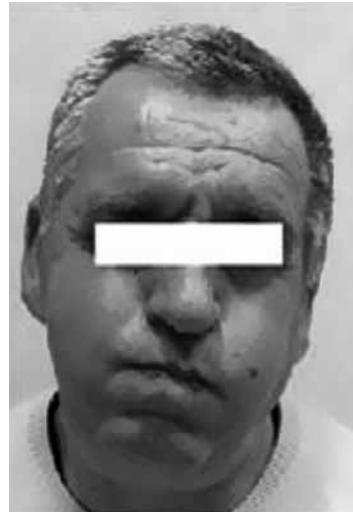

Fig. 4. Functionality of the VII cranial nerve. The patient is perfectly capable of puffing his cheeks, close his eyes and whistle.

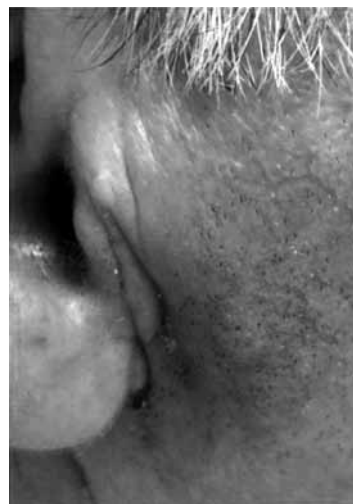

Fig. 5. The final surgical wound.

and dedifferentiated variants. The clear cell variant is called malignant chondroblastoma, but there has been controversy over whether to classify it as a variant of chondrosarcomas or to categorise it separately as malignant chondroblastoma³. The mesenchymal variant is also called the aggressive variant, since 2 of 3 cases arise before the age of 30 and in advanced stages and grades.

Histopathologically, chondrosarcoma of the TMJ seem similar to chondrosarcomas of the head and neck or other regions of the body. Histologically, the lesion is composed of atypical chondrocytes organised in a hyalin matrix where isolated loci of calcification also appear. The classification of this cartilaginous tumour is related to the size that arise in soft tissue areas⁶. T1 tumours are 5 cm or less and T2 tumours are more than 5 cm in the greatest dimension⁷. Surgical treatment is the most effective modality for chondrosarcoma. The most important point is to ensure an adequate safety margin which must be checked from a histological point of view, since residual disease is known to be an important cause of recurrence. It is gen-

erally accepted that radiotherapy should be used for palliative purposes in unresectable cases or as an adjuvant therapy in cases of residual disease rather than as initial treatment.

Prognostic factors in chondrosarcoma are linked to the extent of surgical resection, grade, TNM classification and primary origin sites. The most frequent cause of death is recurrence and not metastasis³.

Pre-operative diagnosis of TMJ chondrosarcoma is difficult and usually not possible because of the rarity of the location and the non-specificity of symptoms. Fine needle aspiration biopsy, although proposed by several authors, does not often provide exact results in this region because it is necessary to distinguish the tumour from osteogenic sarcoma, parotid pleomorphic adenoma and chondroma.

This tumour has a slow growth and is often asymptomatic until it grows to a remarkable size.

There are no pathognomonic findings associated with chondrosarcoma. Single or multiple radiolucent areas can be seen on plain or panoramic films. Bone destruction is a frequent observation, while calcification and ossification, which cause spot densities, are occasionally present. In this case report, the expansive growth of the tumour and its relationship with the TMJ were demonstrated with the use of CT and MRI. In several previously-reported cases of chondrosarcoma, there was evidence of widening of the joint space, which is attributed to condylar resorption. Indeed, local bone destruction was revealed through the use of CT and MRI in all previous cases⁶.

According to Bertoni et al. the most useful features for diagnosis are the following:

- loss of the typical clustering pattern with abundant matrix juxtaposed to areas where the tumour cells are arranged in sheets;
- myxoid change in the matrix;
- hypercellularity with crowding and spindling of the nuclei at the periphery of the lesion;
- presence of necrosis;
- permeation of the trabecular bone and invasion of marrow space⁸.

References

- ¹ Olivera RC, Marques KDS, Mendoca AR, et al. *Chondrosarcoma of the temporomandibular joint: a case report in child*. J Orofac Pain 2009;23:275-81.
- ² Gallego L, Junquera L, Fresno MF, et al. *Chondrosarcoma of the temporomandibular joint. A case report and review of the literature*. Med Oral Patol Oral Cir Bucal 2009;14:39-43.
- ³ Lee SY, Lim YC, Song MH, et al. *Chondrosarcoma of the head and neck*. Yonsei Med J 2005;46:228-32.
- ⁴ Evans HL, Ayala AG, Romsdahl MM. *Prognostic factors in chondrosarcoma of bone: a clinicopathologic analysis with emphasis on histologic grading*. Cancer 1977;40:818-31.
- ⁵ Sesenna E, Tullio A, Ferrari S. *Chondrosarcoma of the temporomandibular joint*. J Oral Maxillofac Surg 1997;55:1348-52.
- ⁶ Gonzalez-perez LM, Sanchez-Sallego F, Perez-Ceballos JL, et al. *Temporomandibular joint chondrosarcoma: case report*. J Craniomaxillofac Surg 2011;39:79-83.
- ⁷ Koch BB, Karnel LH, Hoffman LW, et al. *National cancer database report on chondrosarcoma of the head and neck*. Head and Neck 2000;22:408-25.
- ⁸ Bertoni F, Picci P, Bacchini P, et al. *Mesenchymal chondrosarcoma of bone and soft tissue*. Cancer 1983;52:533-41.

Received: April 2, 2012 - Accepted: April 24, 2012